VIA MEDICA

ORIGINAL ARTICLE

Folia Morphol.
Vol. 63, No. 4, pp. 419–422
Copyright © 2004 Via Medica
ISSN 0015–5659
www.fm.viamedica.pl

The jugular foramen — a morphometric study

O.E. Idowu

Department of Anatomy, College of Medicine, University of Ibadan, Nigeria
Division of Neurological Surgery, Department of Surgery, University College Hospital, Ibadan, Nigeria

[Received 22 July 2004; Revised 5 October 2004; Accepted 5 October 2004]

The jugular foramen (JF) varies in shape and size from side to side in the same cranium, and in different crania, racial groups and sexes. Side dominance is also said to be common. The foramen's irregular shape, its formation by two bones and the numerous nerves and venous channels that pass through it further compound its anatomy.

A morphometric study of 20 (40 JF) adult male Nigerian dry skulls was carried out. A bony bridge completely partitioned the JF in 3 (7.5%) of the JF. There was no tripartite JF. The JF mean length on the right and left were 13.90 mm (11.6–17.0 mm) and 14.11 mm (9.2–20.2 mm), while their widths measured 10.22 mm (6.8––14.4 mm) and 9.57 mm (7.4–12.8 mm) on the right and left respectively. The mean JF area on the right was 437.49 mm (265.35–669.54 mm) and that on the left was 419.48mm (276.46–634.60 mm). Side predominance of one of the JF appeared in 80% of cases. When present, the predominance of the right side was 55%, with 25% on the left. There was a difference in the length and width on each side but no significant difference in the length, width and area of the JF between the two sides. There was a positive correlation between skull width/length and height/length ratio and JF area and length on each side.

In conclusion, complete bony subdivision of the JF was not common among our study population and although the JF was generally larger on the right in our population, this is not statistically significant. A higher skull width/length and height/length ratio is associated with a greater JF length and area.

Key words: intrajugular processes, length, side dominance, width

INTRODUCTION

The jugular foramen (JF) of the human skull is a complex bony canal, which transmits vessels and nerves from the posterior cranial fossa through the skull base into the carotid space [2]. It is the most complex of the foramina through which cranial nerves pass and also difficult to access surgically [6, 8–10, 13, 14].

It is generally said that although the JF is larger on the right side compared to the left, its size as well as its height and volume vary in different racial groups and sexes [11, 17]. The foramen's complex shape, its formation by two bones, and the numerous nerves and venous channels that pass through it further compound its anatomy.

The jugular foramen is the main route of venous outflow from the skull and is characterised by laterality based on the predominance of one of the sides [17]. Ligation of the internal jugular is sometimes performed during radical neck dissection with the risk of venous infarction, which some adduce to be due to ligation of the dominant internal jugular vein.

The 9th, 10th and 11th cranial nerves exit the cranial cavity through the JF. In the syndrome of the JF (Vernet's syndrome), there is paralysis of the 9th, 10th and 11th cranial nerves. These, along with paralysis

Address for correspondence: Dr. O.E. Idowu, Division of Neurological Surgery, Department of Surgery, University College Hospital, Ibadan, Nigeria, e-mail: oeidowu412@yahoo.com

of the 12th cranial nerve (Villaret's syndrome), occur with a retropharyngeal lesion invading the posterior fossa. In some instances, involvement of two or more of these nerves in other combinations is encountered (as in Jackson's vagoaccessory hypoglossal paralysis, Schmidt's vagoaccessory syndrome and Tapia's vagohypoglossal palsy) [15].

Intracranial and extracranial lesions may affect the jugular foramen in addition to intrinsic abnormalities. Pathological processes affecting JF include intracranial meningiomas, paragangliomas (*glomus jugulare*, from the jugular ganglion of the vagus nerve), schwannomas, metastatic lesions and infiltrative inflammatory processes from surrounding structures such as the middle ear [2, 3, 7]. Surgical resection is the treatment of choice in the majority of these cases. Advances in microsurgical techniques have made possible the removal of advanced JF lesions, which were once assumed to be inoperable [16]. As neurosurgeons become bolder in approaching this region, so the need for familiarity with the detailed anatomy of this region becomes greater.

The study was embarked on to examine the anatomy of the JF, including its dimensions, and to discover the degree of predominance, if any, of this opening in adult Nigerian males.

MATERIAL AND METHODS

A total of 40 JF were examined from 20 adult male dry skulls. The skulls were obtained from the osteological collection of the department of Anatomy, College of Medicine, University of Ibadan. Skulls showing pathological changes were excluded.

The lengths, widths and areas of the jugular foramina were determined [11]. Metric measurements (sagittal and transverse diameters) were taken using German Vernier calipers with a precision of 0.1 mm. Each dimension was measured thrice and the mean figure recorded. The data collected was checked for errors prior to analysis.

Data analysis was performed with SPSS version 11. The mean standard deviation (SD) and ranges of each dimension and derived index were computed. Right and left differences were analysed. A comparison was made of the means of the dimensions using the Student's t-test. The association between continuous variables was investigated by means of Pearson's correlation coefficient. The laterality coefficient was also calculated. This was the ratio between the cross-section area of the two JF, the greater one and the smaller. A probability (p) of less than 0.05 was considered statistically significant.

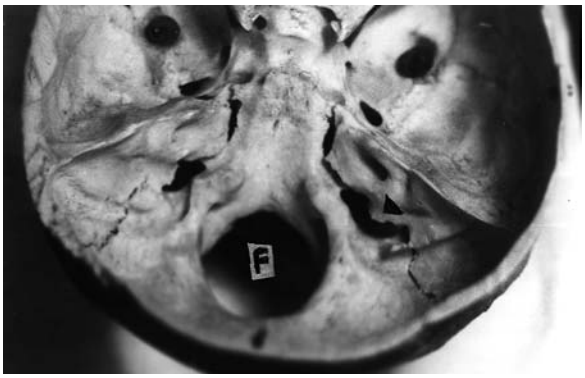

Figure 1. Endocranial view of the jugular foramen with the right foramen larger than the right; F — foramen magnum; Arrow head — intrajugular process.

RESULTS

Morphology

The jugular foramen is located between the temporal bone and the occipital bone. Its intracranial orifice is below the internal auditory meatus and superolateral to the intracranial orifice of the hypoglossal canal (Fig. 1). It is situated with its long axis oriented from anteromedial to posterolateral parallel to the petroclival fissure, being configured around the sigmoid and inferior petrosal sinuses. One cannot see through the foramen when viewing the skull directly from above or below because of its roof, formed by the lower surface of the petrous temporal bone. It has a large oval lateral component, the sigmoid part, which receives the drainage of the sigmoid sinus, and a small medial part, termed the petrosal part, which receives the drainage of the inferior petrosal sinus. The view of the JF from below reveals the part of the temporal bone forming the dome of the jugular bulb rather than a clear opening. The intrajugular process partly divides the foramen into an anteromedial *par nervosa* and a larger posterolateral *pars vascularis*. In 3 JF (7.5%), a bony bridge completely partitioned JF.

JF dimensions and relations

The mean breadth/length, height/length and height/width ratios of the skulls taken together were 0.80 (0.74–0.86), 0.79 (0.72–0.86) and 0.98 (0.93–1.00) respectively. The JF mean length on the right and left were 13.90 mm (11.6–17.0 mm) and 14.11 mm (9.2–20.2 mm), while their widths measured 10.22 mm (6.8–14.4 mm) and 9.57 mm (7.4–12.8 mm) on the right and left respectively (Table 1). The mean area on the right was 437.49 mm

Table 1. The jugular foramen dimensions

	RTL	LTL	RTW	LTW	RAREA	LAREA
Mean	13.90	14.11	10.22	9.57	437.49	419.48
SD	1.48	3.13	2.67	1.84	114.29	106.52
Minimum	11.60	9.20	6.80	7.40	265.35	276.46
Maximum	17.00	20.20	14.40	12.80	669.54	634.60
Percentiles						
3rd	11.60	9.20	6.80	7.40	265.35	276.46
25th	13.20	11.60	7.93	8.03	340.46	368.17
50th	13.60	14.45	9.00	9.50	442.05	385.57
75th	14.80	16.00	12.20	10.60	503.28	492.36
97th	17.00	20.20	14.40	12.80	669.54	634.60

RTL — right length, LTL — left length, RTW — right width, LTW — left width, RAREA — right area, LAREA — left area, SD — standard deviation, all measurements in mm

(265.35–669.54 mm) and that on the left was 419.48 mm (276.46–634.60 mm). A predominance of one of the JF appeared in 80% of cases. When present, the predominance of the right side was 55% with 25% on the left. There was no statistically significant difference between the two sides in the length, width and area of the JF, but there was a statistical difference in the length and width on each side. There was a positive correlation between lengths, and areas on both sides but no correlation between length and width on each side (Table 2, 3).

Statistical analysis did show significant positive correlation between skull width/length and height/ /length ratio and JF area and length on each side.

DISCUSSION

The jugular foramen is located at the posterior end of the petro-occipital structure and is formed by the petrous temporal bone anterolaterally and the occipital bone posteromedically [1]. It courses anteriorly, then laterally and finally inferiorly through the skull base. Anteriorly it is separated from the inferior carotid opening by a bony ridge, the carotico-jugular spine. Lateral to the jugular foramen is the hypoglossal canal, and an osseous bar separates the two.

The structures that traverse the JF are the sigmoid sinus, jugular bulb, inferior petrosal sinus, meningeal branches of the ascending pharyngeal and occipital arteries, the 9th – 11th cranial nerves with their ganglia, the tympanic branch of the glossopharyngeal nerve (Jacobson's nerve), the auricular branch of the vagus (Arnold's nerve) and the cochlear aqueduct [8]. The difficulties in exposing this canal are created by its deep location and the surrounding vital structures, such as the carotid artery anteriorly, the hypoglossal nerve medially, the facial nerve laterally and the vertebral artery inferiorly. All these important structures require careful dissection during access to this canal.

Hovelacque [6] was the first to propose the subdivision of JF. The foramen is divided by a fibrous or bony septum that joins the jugular spine of the petrous bone to the jugular process of the occipital bone, the anteromedial compartment (*pars nervosa*) and a posterolateral compartment (*pars vascularis*). The *pars nervosa* receives the 9th cranial nerve, inferior petrosal sinus and the meningeal branch of the ascending pharyngeal artery, while the remaining structures pass via the *pars vascularis*.

Table 2. Student's t test and Pearson correlations of the various continuous variables

Variables	Student's t	(p-value)	r	(p-value)
RTL – LTL	–0.390	(0.701)	0.695	(0.001)
RTW – LTW	1.443	(0.165)	0.658	(0.002)
RAREA – LAREA	1.060	(0.303)	0.763	(0.000)
RTL – RTW	5.303	(0.000)	–0.043	(0.856)
LTL – LTW	4.975	(0.000)	–0.304	(0.192)

RTL — right length, LTL — left length, RTW — right width, LTW — left width, RAREA — right area, LAREA — left area, r — Pearson correlation coefficient; $p < 0,05$

Table 3. The pearson correlation coefficient and p-value of the continuous variables

		RL	LL	RW	LW	RAREA	LAREA
RL	r	–	0.695	–0.043	–0.412	0.249	0.333
	p	–	0.001	0.856	0.071	0.290	0.151
LL	r	0.695	–	0.334	–0.304	0.557	0.754
	p	0.001	–	0.151	0.192	0.011	0.000
RW	r	–0.043	0.334	–	0.658	0.843	0.762
	p	0.856	0.151	–	0.002	0.000	0.000
LW	r	–0.412	–0.304	0.658	–	0.371	0.382
	p	0.071	0.192	0.002	–	0.107	0.096
RAREA	r	0.249	0.557	0.843	0.371	–	0.763
	p	0.290	0.011	0.000	0.107	–	0.000
LAREA	r	0.333	0.754	0.762	0.382	0.763	–
	p	0.151	0.000	0.000	0.096	0.000	–

RL — right length, LL — left length, RW — right width, LW — left width, RSIZE — right size, LSIZE — left size; RAREA — right area, LAREA — left area, r — Pearson correlation coefficient; $p < 0.05$

Tekdemir et al. [16] observed no partition in his series while Ekinci et al. [5] found bony bridges in 20% and tripartite JF in 0.7%. Rhoton and Buza [13] noted 26% bony bridges; this was bilaterally represented in 8%. A bony bridge in 3 (7.5%) of the JF with bilateralism in 1 skull was found in this series. Rhoton et al. and DiChiro et al. observed a separate bony canal anterior to the *pars nervosa* in 6% of skulls, while Patridge noted a frequency of 25% [4, 12, 13]. This bony canal was for the exit of the IX cranial nerve. This review did not note a separate bony canal anterior to the *pars nervosa*. The smaller *pars nervosa* is relatively consistent in size compared with the larger and more variable *pars vascularis* [4].

Navsa and Kramer noted a significantly larger exocranial area on the right in blacks but one of normal size in whites in South Africa [11]. Predominance of JF appeared in 83% of cases in Wysocki's series and the predominance of the left and the right side were equally possible [17]. In 61.4% of cases the right JF was larger in Ekinci's series, while Rhoton et al noted that 68% of JF were larger on the right, 12% equal and 20% smaller [5, 13]. None of these studies tested for any significant statistical difference. In this present study the right JF was larger in 55% of cases, while in 25% of cases it was larger on the left; this, however, was not statistically significant.

CONCLUSION

The total bony subdivision of the JF is not common in our environment. The jugular foramen is generally larger on the right in our population but this is not statistically significant. A higher width/ /length and height/length ratio is associated with a greater JF length and area.

REFERENCES

1. Williams PL, Bannister LH, Berry MM, Collins P, Dyson M, Dussek JE, Ferguson MWJ (eds.) (1995) Gray's anataomy. 38th Ed. Edinburgh: Churchill Livingstone, pp. 567.
2. Chong VF, Fan YF (1998) Radiology of the jugular foramen. Clinical Radiology, 53: 405–416.
3. Chong VFH, Fan YF (1996) Jugular foramen involvement in naso-pharyngeal carcinoma. J Laryng Otology, 110: 897–900.
4. Di Chiro G, Fisher RL, Nelson KB (1964) The jugular foramen. J Neurosurgery, 21: 447–452.
5. Ekinci N, Unur E (1997) Macroscopic and morphometric investigation of the jugular foramen of the human skull. J Anatomy, 72: 525–529.
6. Hovelacque A (1967) Osteologie. Paris, G Doin and Cie. pp. 155–156.
7. Kanemoto Y, Ochiai C, Yoshimoto Y, Nagai M (1998) Primarily extracranial jugular foramen neurinoma manifesting with marked hemiatrophy of the tongue: case report. Surgical Neurology, 49: 534–537.
8. Katsuta T, Rhoton AL Jr, Matsushima T (1997) The jugular foramen. Microsurgical Anatomy. Neurosurgery, 41: 149–201.
9. Kveton JF, Cooper MH (1988) Microsurgical anatomy of the jugular foramen region. Am J Otol, 9: 109–112.
10. Lang J, Weigel M (1983) Nerve-vessel relations in the region of the jugular foramen. Anat Clin, 5: 41–58.
11. Navsa N, Kramer B (1998) A quantitative assessment of the jugular foramen. Anatomischer Anzeiger, 180: 269–273.
12. Patridge EJ (1918) The relations of the glossopharyngeal nerve at its exit from the cranial cavity. J Anat, 52: 332–334.
13. Rhoton AL Jr, Buza R (1975) Microsurgical anatomy of the jugular foramen. J. Neurosurgery, 42: 541–550.
14. Schwaber MK, Netterville JL, Maciunas R (1990) Microsurgical anatomy of the skull bone. Am J Otol, 11: 401–405.
15. Talbert OR (1990) General methods of clinical examination. Youman's Neurological Surgery, 3rd Ed. W.B. Saunders Company, pp. 21.
16. Tekdemir I, Tuccar E, Aslan A, Elhan A, Deda H, Ciftci E, Akyar S. (1998) The jugular foramen:a comparative radioanatomic study. Surgical Neurology, 50: 557–562.
17. Wysocki J, Chmielik LP, Gacek W (1999) Variability of magnitude of the human jugular foramen in relation to condition of the venous outflow after ligation of the internal jugular vein. Otolaryngologia, 53: 173–177.